

Consensus on Genitourinary Trauma

The first in this series of five papers concerns the evaluation and management of renal injuries. The authors of this paper come from four continents and seven countries, and they reviewed all papers on renal injury published between 1966 and April 2002. The results of the authors' deliberations are present here as a consensus document.

Evaluation and management of renal injuries: consensus statement of the renal trauma subcommittee

R.A. SANTUCCI, H. WESSELLS¹, G. BARTSCH², J. DESCOTES³, C.F. HEYNS⁴, J.W. McANINCH⁵, P. NASH⁶ and F. SCHMIDLIN⁷

Departments of Urology, Wayne State University School of Medicine, Detroit, ¹Harborview Medical Center and University of Washington School of Medicine and Harborview Injury Prevention Research Center, Seattle, Washington, USA, and ²University of Innsbruck, Innsbruck, Austria; ³CHU de Grenoble, Service D'Urologie et de Transplantation Renale, Grenoble, France; ⁴Departments of Urology, ⁵University of Stellenbosch and Tygerberg Hospital, South Africa and ⁶University of California School of Medicine, San Francisco, USA; ⁷St. George Private Medical Center, Sydney, Australia, and ⁷Department of Urology, University Hospital, Geneva, Switzerland

Accepted for publication 25 February 2004

OBJECTIVE

To determine the optimal evaluation and management of renal injuries by review of the world's English-language literature on the subject.

METHODS

A consensus conference convened by the World Health Organization and the Société Internationale d'Urologie met to critically review reports of the diagnosis and treatment of renal trauma. The English-language literature about renal trauma was identified using Medline, and additional cited works not detected in the initial search obtained. Evidence-based recommendations for the diagnosis and management of renal trauma were made with reference to a five-point scale.

RESULTS

There were many Level 3 and 4 citations, few Level 2, and one Level 1 which supported clinical practice patterns. Findings of nearly 200 reviewed citations are summarized.

CONCLUSIONS

Published reports on renal trauma still rely heavily on expert opinion and single-institution retrospective case series. Prospective trials of the most significant issues, when possible, might improve the quality of evidence that dictates the behaviour of practitioners.

KEYWORDS

kidney, injury, surgery, nephrectomy, renorrhaphy, trauma

INTRODUCTION

Renal parenchymal lacerations and vascular injuries can lead to significant morbidity and mortality, but the incidence, severity and optimal treatment of renal injuries have not been established in population-based cross-sectional studies or prospective trials. Hundreds of published reports have discussed the treatment of renal trauma, but regional differences in injury mechanisms and treatment preferences may make it



inappropriate to generalize the findings of specialized centres to practitioners worldwide. Furthermore, no longitudinal studies of outcomes have been carried out. To codify the evidence supporting the evaluation and management of renal injuries, a consensus conference was convened by the WHO, and organized by the Société Internationale d'Urologie (SIU). The abbreviated findings of the committee were presented at the 2002 Congress of the SIU in Stockholm. This is the report of the Renal Trauma Subcommittee of this WHO/SIU Genitourinary Trauma Consensus Conference.

METHODS

SUBCOMMITTEE COMPOSITION

The organizers of the SIU selected renal trauma subcommittee members from four continents and seven countries, including Africa, Europe, Australia, and North America. Each member was a urologist with special expertise in the field of renal injury, based on training, experience and research publications.

SEARCH CRITERIA

A Medline search using PubMed was made to include articles from 1966 to April 2002. MESH headings used in the search included kidney, injuries, renal trauma, renorrhaphy, renovascular hypertension, nephrectomy, Page kidney, radiology, imaging, scan, arteriography, magnetic resonance, computed tomography, and ultrasound. Articles were limited to English-language reports and numbered >1400. Pertinent peer-reviewed articles were retrieved and papers referenced in bibliographies but not initially retrieved from Medline were also examined.

LEVELS OF EVIDENCE

The level of evidence that supported each major point was categorized into five divisions as follows: (1) supportive evidence from randomized trials; (2) supportive evidence from prospective studies; (3) supportive evidence from retrospective studies; (4) supportive evidence from case series or case reports; (5) expert opinion.

The subcommittee met and developed consensus opinions about the appropriate

Variable	Series					TABLE 1 The epidemiology of renal trauma (from [1])
	[2]	[173]	[66]	[7]	[1]	
Rate of renal injury, %	2.8	3.25	N/A	1.4	1.2	<i>N/A, not available; Major injury defined as AAST grades 2–5 or ICD-9 code for laceration, parenchymal disruption, or vascular injury.</i>
N	154	132	2254	227	6231	
Blunt	93.5	95.4	89.8	93.4	81.6	
Penetrating	6.5	4.6	10.2	6.6	18.4	
Minor injuries	92	72	91.1	81.7	82.5	
Major injuries	8	28	8.9	18.3	17.5	
Renal exploration	N/A	7.4	7.4	7.1	13	
Nephrectomy	3.8	3.2	0.8	N/A	7	

management of renal injuries, as supported by the differing levels of evidence in the publications. The findings of the subcommittee were presented at the SIU Congress in Stockholm in September 2002 for further input from the general audience.

RESULTS

The evaluation and management of renal injuries has developed over several decades as a result of improved imaging and accumulating experience with operative and nonoperative therapy. There are reported randomized trials (Level 1) including one in the field of renal trauma. Large prospective and retrospective cohort studies support a consensus on the epidemiology, imaging criteria and management of renal injuries, while most studies cited in this document are retrospective case series. The highest level of evidence is listed for each subsection of the paper. Support for particular statements that depend on a lower level of evidence are included in the text.

EPIDEMIOLOGY

INCIDENCE (LEVEL 3)

Single institution series commonly report the number of trauma patients with kidney injuries, the proportion being 1.4–3.25% (Table 1). One study reported the incidence of renal injury, on a population basis, as 4.9 per 100 000 persons [1]. Estimating the number of renal injuries worldwide is difficult, because of the differing mechanisms in developed vs developing countries. By extrapolating from USA data we estimate the number of renal injuries each year worldwide at ≈245 000.

DEMOGRAPHICS (LEVEL 3)

Renal trauma is a disease of the young; the mean age in large retrospective series is 20–30 years [2–6]. In a population-based study, 70–80% of renal injuries occurred in those aged <44 years [1]. Renal injuries are more common in males (Level 3) [2–6]. Although this difference has been attributed to male involvement in high-risk activities (e.g. high-speed motor vehicle crashes, contact sports, violent crime), in one study the difference in prevalence of renal injury between genders existed even when controlling for mechanism, age and injury severity score [1].

MECHANISMS (LEVEL 3)

The vast majority of renal injuries result from blunt mechanisms, although there is some geographical variation. In Europe, 97% of renal injuries are blunt; in Canada 93% [7], in the USA, 82–95% [1,8–10], in South Africa 25–84% [11,12] and in rural Turkey 31% [13]. Blunt trauma is also responsible for the overwhelming majority of paediatric renal injury (Level 3) [14–19].

Motor vehicle crashes and falls account for most kidney trauma in the developed world [20]. The proper use of seat belts and other preventive measures could have a major impact on the incidence of renal trauma (Level 5). However, penetrating mechanisms are much more likely to cause severe renal injuries requiring operative intervention and nephrectomy [8]. Motor vehicle crashes and war will become major burdens of disease in the 21st century, and thus the number of renal injuries worldwide is expected to increase [21].

The reported proportion of renal injuries from penetrating mechanisms is 4.6–87% [1,2,22–26]. These large variations are a result of differences in the era of reporting, types of

trauma prevalent in different geographical areas, and referral patterns to trauma centres. Patients admitted to one hospital with penetrating abdominal injuries were found to have renal trauma in 4–8% [27]. In another study, penetrating injuries comprised 19% of county hospital renal trauma cases and only 1.2% of private hospital cases [28]. Overall, 18.4% of renal injuries were caused by a penetrating mechanism in a study of 6231 renal injuries, representing the injury experience of 62% of the USA population [1]. The likelihood of a renal injury is higher with firearm than stabbing injury.

Civilian violence is decreasing in the USA [1]; the rate of penetrating injury was significantly higher in the 1960s to early 1990s than at present [27,28]. Wartime renal injuries to USA soldiers also appear to be decreasing. In the Vietnam war \approx 32% of urological injuries involved the kidney [29]. The use of flak jackets in the Gulf War caused a shift from abdominal to pelvic genitourinary wounds (17% renal vs 83% pelvic and genital) [30]. The Kuwaiti soldier's experience (with no body armour) during the same war noted more gunshot wounds than seen in USA soldiers, and 33% of all genitourinary injuries affected the kidney [31]. In Croatia, 56% of urogenital injuries were penetrating kidney injuries, 75% of which were from fragmentation devices such as land mines [32]. Injuries to unprotected civilians as a result of fragmentation devices may represent a significant future cause of renal trauma.

INJURY SEVERITY (LEVEL 3)

Most renal injuries are minor. Significant renal injuries, including lacerations and vascular injuries, account for 27–68% of patients with a penetrating mechanism compared to 4–25% for blunt [5,24,26,33,34]. Geography, mechanisms of injury and grading systems affect the proportions reported [1,8,35–37]. There is usually an association between mechanism and overall injury severity, and likelihood and severity of renal injury [1,27,33,38]. Associated injuries are common and occur in 20–94% of renal trauma cases [39].

PATHOPHYSIOLOGY

BLUNT RENAL TRAUMA (LEVEL 4)

Motor vehicle crashes and falls are obvious causes of renal injury. However, only by

assessing blunt renal trauma in terms of injury biomechanics can a better understanding be gained of injury mechanisms. New measures to prevent or reduce the severity of injury may result from such advances. In addition, refined mechanistic models may improve clinical trauma management by defining precise criteria for triage of patients for higher echelons of care.

The kidneys are relatively well protected by their anatomical location, lying high in the retroperitoneum with the abdominal viscera anteriorly and the back muscles and spine posteromedially. Only major forces applied to the body result in renal injuries, which explains the high percentage of coexisting abdominal lesions in major renal trauma [40,41].

Renal pedicle injuries are frequently caused by deceleration injuries [41]. The kidneys lie in the retroperitoneal space surrounded by fat, which is enveloped by Gerota's fascia. The renal pedicle and the PUJ form the major attachment sites. Any deceleration force will primarily act on such attachment sites and create renal pedicle injury (thrombosis or rupture) if the tolerance limits are surpassed [41].

More than 90% of renal injuries represent lesions of the parenchyma or larger segmental vessels, and understanding the biomechanics of these injuries is more complicated. During blunt impact the ribs and/or the abdominal wall hit the kidneys. The resulting organ acceleration may lead to a collision with its environment, the spine and the back muscles representing the closest solid and rigid structure. Renal parenchymal and vascular injury may therefore result from the direct contact of the kidney with the impact itself or in combination with a secondary collision.

From a biomechanical perspective renal injury is expected whenever some characteristic variables, e.g. absorbed energy, acceleration or shear stress, exceed a critical tolerance limit. Experimental loading and simulation studies revealed that clinically observed parenchymal injuries are caused by a bending/shear mechanism. The trauma susceptibility of the kidneys increases with increasing impact velocity, as the injury threshold (specific energy density for rupture) decreases with increasing impact speed [41–43]. Further

studies will focus on the overall biomechanical response of the kidney as part of the abdominal cavity (energy absorption, interaction with surrounding structures).

PENETRATING INJURIES (LEVEL 4)

Stab and firearm wounds of the kidney differ markedly in the type and severity of renal injury sustained, effect on surrounding tissues and likelihood of associated injuries [27,44–46]. Gunshot wounds may be caused by a low- or high-velocity missile, which causes direct tissue injury as well as a blast effect to the adjacent tissue [27]. In firearm injury the crush of tissue that is struck by the bullet (the permanent cavity) and the stretch of surrounding tissue (the temporary cavity) are the wounding mechanisms [13]. The wound profile of a low-velocity missile injury is similar to that of a stab wound. However, higher missile velocities (>350 m/s) may result in greater tissue damage. Moreover, if the bullet tilts along its long axis in relation to its path (termed yaw) an area of tissue wider than its diameter can be damaged (Fig. 1). Wounds from high-velocity missiles should be considered contaminated, because they may bring in clothing or other foreign material from the entrance site [47]. This, and the potential for devascularized or poorly vascularized tissues after high-velocity gunshot wounds, suggests that these patients should be treated prophylactically with antibiotics (Level 5).

Vital renal structures such as the pelvis, hilum and pedicle are directed towards the midline of the body. Penetrating injury through the anterior abdomen is thus more likely to injure these vital structures and cause major renal injury (Fig. 2) [44]. Flank wounds posterior to the anterior axillary line are more likely to injure peripheral and nonvital renal structures such as the parenchyma, resulting in less severe injuries. This explains the greater success rate in the conservative management of posterior stab wounds involving the kidney. Gunshot wound analysis using a similar model is not useful because of there is less predictability about bullet velocity, trajectory and secondary blast effects [44]. For stab wounds, the site of penetration has a weak relationship to the grade of injury [48].

No studies have specifically examined how weapon and/or missile characteristics affect the severity of renal injury in animal models or clinical studies. Nevertheless, every effort

should be made to determine the exact nature of the weapon when evaluating patients who have had a penetrating renal injury.

RENAL TRAUMA AND PRE-EXISTING KIDNEY LESIONS (LEVEL 3)

The preponderance of evidence suggests that pre-existing renal lesions increase the vulnerability of kidneys in blunt renal trauma [49–58]. There have been four studies reviewing 733 adult and paediatric patients with renal abnormalities and trauma [51,53,57,58]. In these studies pre-existing renal abnormalities were found in 4.4–19% [58] of adult patients with blunt renal trauma. The percentage of abnormal kidneys was considered higher in children, at 12.6–35% [4,51,53,57]. With decreasing frequency, the following types of renal lesions were found: hydronephrosis (PUJ, stone, reflux), cysts, tumours and abnormal kidney position. In all cases patients were unaware of the underlying disorder at the time of the accident. The cause of the predisposition has been attributed to reduced tissue strength in hydronephrotic kidneys, altered tissue deformation of renal cortex in the presence of a fluid-filled lesion (cyst, hydronephrosis), the relatively larger body proportion of paediatric kidneys, and their lesser protection from the more pliable thoracic cage, weaker abdominal musculature and less perirenal fat [56,58].

CLASSIFICATION OF RENAL INJURY

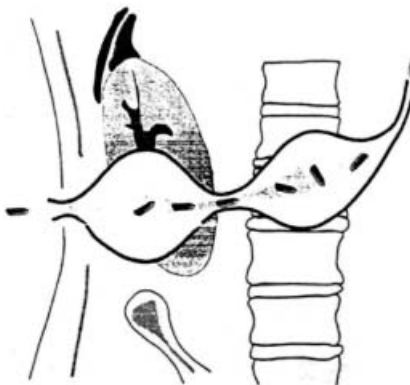
The accurate and reproducible classification of injury severity is critical to standardize trauma research. The American Association for the Surgery of Trauma (AAST) has developed organ-injury severity scales for each of 32 organs and organ systems (Level 5). The severity scale for the kidney proposed in 1989 [59] has supplanted several previous grading systems and corresponds to the Abbreviated Injury Scale used to determine the injury severity score. The AAST scale for the kidney was validated in 2001 by a retrospective review of 2467 patients (Level 3) [8] and by another study in which serious negative outcomes were associated with higher renal injury severity (Level 4) [60]. In some administrative databases, injury severity is based on ICD-9 diagnosis; software can be used to convert the ICD-9 grade to that of the Abbreviated Injury Scale [61].

TABLE 2 The AAST organ injury severity scale [59]

Grade*	Type	Description
I	Contusion	Microscopic or gross haematuria, urological studies normal
	Haematoma	Subcapsular, not expanding with no parenchymal laceration
II	Haematoma	Not expanding perirenal haematoma confirmed to renal retroperitoneum
	Laceration	<1.0 cm parenchymal depth of renal cortex with no urinary extravasation
III	Laceration	>1.0 cm parenchymal depth of renal cortex with no collecting system rupture or urinary extravasation
	Laceration	Parenchymal laceration extending through renal cortex, medulla and collecting system
IV	Vascular	Main renal artery or vein injury with contained haemorrhage
	Laceration	Completely shattered kidney
	Vascular	Avulsion of renal hilum which devascularizes kidney

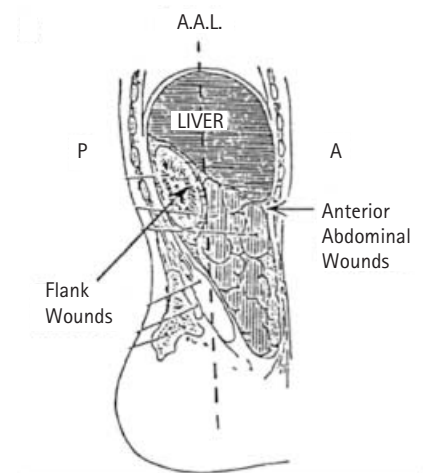
*Advance one grade for bilateral injuries up to grade III. Accessible online at <http://www.aast.org/injury/injury.html>.

FIG. 1. Schematic drawing of the blast effect injury caused by the yawing of a high velocity missile [13].



The AAST scale (Table 2) allows an accurate description of most renal injuries, although modifications to better reflect clinical outcomes with severe injuries may be needed (Level 5). For example, 'shattered' kidneys with deep parenchymal lacerations that occur in combination with significant vascular injuries (renal artery thrombosis or segmental arterial laceration) often require nephrectomy, and if repaired, function poorly. A Grade V designation best reflects these serious risks and outcomes. In contrast, at some centres a kidney with two or more Grade III or IV corticomedullary lacerations is incorrectly categorized as a Grade V shattered kidney. The term 'shattered' kidney needs to be clarified to maintain its original use to describe irretrievable renal injury, often associated with dispersion of the avulsed portions, vascular collapse and hilar injury. Such destroyed kidneys have worse early and late

FIG. 2. Schematic drawing of abdomen to show that penetrating injury anterior to the anterior axillary line (AAL) is more likely to injure vital renal structures such as the pelvis, hilus and pedicle and cause major renal injury. Flank wounds posterior to the AAL are more likely to injure peripheral and nonvital renal structures such as the parenchyma, resulting in less severe injuries [44].



outcomes than patients with multiple cortical lacerations; the latter should be classified as Grade IV. Future changes in the scale may be required as improved imaging methods allow segmental arterial contrast medium extravasation to be identified, quantitative measurements of haematoma volume, or other variables that in the future may better predict outcomes for renal injury (Level 5).

TABLE 3 Number of patients with major renal injuries in adults with microhaematuria and hypotension (SBP <90 mmHg), and in children

Ref	Year	N Patients	Major injuries
Adults			
[24]	1985	221	0
[174]	1986	494	5*
[3]	1987	365	0
[34]	1989	623	0
[173]	1991	37	0
[172]	1992	317	0
[175]	1994	605	1+
[66]	1995	744	2+
Total		3406	8 (0.2%)
Children			
[38]	1983	140	9
[176]	1988	47	0
[177]	1989	23	0
[178]	1991	155	2
[179]	1993	47	0
[180]	1995	26	0
[19]	1999	110	0
Total		548	11 (2%)

*Four of five patients had associated injuries; one patient without associated injury had a renal laceration; †One of the two grade 3 lacerations was discovered at exploratory laparotomy for associated injuries and underwent renal exploration and repair; ‡Patient had major renal laceration, grossly positive peritoneal lavage, and lethal closed head injury.

INITIAL EVALUATION OF THE PATIENT WITH RENAL INJURY

The evaluation of renal trauma must be tailored to the hospital setting and clinical condition of the patient. The haemodynamic status must be determined at the initial trauma assessment. In the stable patient, specific data can be collected that will determine the appropriate evaluation and management. The forces involved in renal injury need to be quantified in the case history and can help in determining the need for radiographic imaging. The physical examination can ascertain the location of penetrating entry and exit wounds, flank ecchymosis, rib fractures, and the presence of a large perinephric haematoma [48]. Vital signs recorded in the field and on arrival at the hospital are of primary importance in managing renal trauma [62]. Heart rate, systolic blood pressure (SBP) and respiratory

rate can be used to estimate the amount of blood that may already have been lost. The lowest recorded SBP is also used in conjunction with other information to determine whether renal imaging is indicated [34].

URINE ANALYSIS (LEVEL 3)

The urine analysis is the most important laboratory study used to assess the patient with suspected renal injury. Haematuria is a common sign of renal trauma, being present in 80–94% of cases [27]. However, there is no absolute relationship between the presence, absence or degree of haematuria and the severity of the renal injury [26,27,63,64]. Haematuria is frequently transient, thereby indicating the need for urine analysis on the first aliquot of urine [24]. Either dipstick or microscopic evaluation is acceptable [65]. Blood may be completely absent from the urine after some types of renal trauma, including pedicle injury and penetrating mechanisms [23]. In penetrating trauma the degree of haematuria correlates especially poorly with the severity of renal injury. Conversely, in blunt trauma the distinction between gross and microscopic haematuria has predictive value in determining the likelihood of a major injury [34].

PENETRATING TRAUMA (LEVEL 3)

Large retrospective studies have shown that about half of all patients with penetrating trauma and haematuria will have grade 3, 4 or 5 renal injury. Thus it is strongly recommended that patients with suspected penetrating kidney injuries have complete radiographic staging or renal exploration. A high index of suspicion must be maintained for renal injury with all gunshot and stab wounds to the chest, flanks and abdomen. Haemodynamic instability may preclude standard radiographic imaging, in which case intraoperative evaluation with renal exploration or IVU may be indicated (see below).

BLUNT TRAUMA IN ADULTS (LEVEL 2)

The degree of haematuria and systolic blood pressure can be used to predict the likelihood of major blunt renal injury in adults. With gross haematuria, or microhaematuria and a SBP of <90 mmHg, the proportion of blunt trauma patients sustaining major injury

(12.5%) justifies imaging [34]. In adult patients (>16 years old) with blunt trauma, microhaematuria, and a SBP of >90 mmHg, only 0.2% will have a major renal injury (Table 3). The criteria used to determine which patients require radiographic assessment have been established for adults, based on clinical predictors of significant renal injury in 1146 renal trauma patients [34]. Later, the concept was further validated by retrospective review of ≈400 more patients for a total of 1588 [66], some of whom were prospectively studied. Thus, haemodynamically stable adults with blunt trauma should undergo radiographic evaluation if they have gross haematuria, microhaematuria and a SBP of <90 mm/Hg.

Even in the absence of haematuria, certain injury mechanisms should raise the possibility of unrecognized renal trauma; falls from heights, high-speed motor vehicle accidents and those with multiple associated injuries. In a recent review of free-fall patients, severe renal injury was rare, did not correlate with the height of the fall, and five of 24 patients with high-grade injuries had no haematuria [63]. Despite the absence of haematuria or shock, vertical deceleration injuries, in particular those associated with multiple-system injuries and/or physical signs of potential renal injury (flank ecchymosis, flank pain), demand renal imaging. After a fall from height the index of suspicion for injuries to the PUJ and renal vasculature should be high [63].

BLUNT TRAUMA IN CHILDREN (LEVEL 3)

There is controversy in published reports about whether the criteria for imaging adult patients with blunt trauma [34] apply to children. The weight of evidence suggests that most children with microscopic haematuria do not require imaging (Table 3). Because hypotension is a late manifestation of hypovolaemia in children, blood pressure is not considered a reliable criterion for imaging. No prospective studies have determined the sensitivity and specificity of haematuria in the diagnosis of childhood renal injury. However, it appears that very few clinically significant renal injuries would be missed if, in children with blunt trauma, only those with >50 red blood cells/high-power field underwent imaging [15–17,19]. The effect of missed injuries on the outcome is currently unknown, although the chance of serious morbidity or mortality is likely to be very low [67–69].

Haemodynamically stable children with blunt trauma should undergo radiographic evaluation if they have gross haematuria or >50 red blood cells/high-power field on microscopic urine analysis.

INITIAL IMAGING OF RENAL TRAUMA

The four main objectives of radiographic imaging of renal trauma are to accurately stage the injury, recognize pre-existing pathologies of the injured kidney, document the function of the opposite kidney, and identify associated injuries to other organs. In the past, IVU and renal arteriography were used for staging renal trauma. The cornerstone of radiographic staging of haemodynamically stable renal trauma is now CT.

As outlined in the previous section, not all patients with renal injuries require a radiographic evaluation. The decision to image should be based on history, mechanism of injury, physical findings, laboratory studies and clinical status. The main goal of imaging is to differentiate injuries requiring early operative management from those amenable to deferred surgical treatment or nonoperative management.

Initial imaging must be adjusted to the stability of the patient, and is modified when immediate surgery is required because of bleeding and shock. Follow-up imaging, to assess the response to therapy or identify complications, differs significantly from the requirements of the initial radiographic assessment and will be discussed separately

CT (LEVEL 4)

Data from numerous retrospective case series support abdominal CT with intravenous injection with contrast medium as the recommended radiographic study for initially evaluating patients with suspected renal injury. CT accurately identifies vascular injury, parenchyma laceration, urinary extravasation and perirenal haematoma [33,70]. Arteriovenous phase scanning is necessary to detect arterial extravasation, which can be diagnosed early after contrast medium injection when using helical CT. Injury of the renal collecting system may be missed by this first evaluation, so a repeat scan 10–20 min after the injection is recommended [71,72].

The value of CT in delineating abdominal organ injuries is well substantiated [26]. Thus any CT intended to image the kidneys should also be adjusted to identify other solid-organ injuries. The protocol in use at many trauma centres, based on expert opinion and level 3–4 evidence, is the following: helical CT of abdomen and pelvis, with an arterial and/or portal venous phase from diaphragm to ischial tuberosities, and 10 min delayed images, kidneys through to ischial tuberosities. The delayed films may be omitted when the kidneys are deemed normal, and no perinephric, retroperitoneal, pelvic or perivesical fluid is present (Level 5).

INTRAOPERATIVE ONE-SHOT IVU (LEVEL 4)

Haemodynamically unstable patients with suspected major renal injuries require alternative imaging. When blunt or penetrating injuries cause massive haemorrhage and require immediate laparotomy, CT is contraindicated. While the utility of the emergency room IVU has been questioned [73], haematuria in these patients requires further assessment. Intraoperative one-shot IVU, in conjunction with findings at laparotomy, can be used to exclude life-threatening renal injury and confirm the existence of a contralateral functioning kidney [74].

One-shot IVU depends on rapid bolus administration of contrast (2 mL/kg). A single plain abdominal X-ray obtained 10 min after injection may detect delayed excretion or urinary extravasation. In a recent study, a normal film obviated the need for renal exploration in 32% of patients [74]. Profound hypotension, visceral oedema, warming blankets and massive fluid resuscitation may limit the resolution of the study.

ALTERNATIVE IMAGING METHODS

Not all centres treating injured patients will have access to CT. In addition, the radiation dose associated with helical CT is not insignificant, and for children this method should be used judiciously. Reactions to contrast media, although rare, can also be life-threatening [75]. IVU and ultrasonography (US) can both provide important information about the vascular and parenchymal integrity of the paediatric kidney. However, these methods are more operator-dependent and provide less detail

about extravasation, haematoma size and associated injuries.

US (LEVEL 4)

US may, in experienced hands, provide important information about a renal injury [76], but in most cases the resolution is inferior to CT, and major renal injuries may not be recognized [77,78]. In some trauma centres US is commonly used in the emergency room because it is rapid and not invasive. However, prospective studies comparing the sensitivity and specificity of US to CT for identifying renal injuries are lacking. In departments where CT is easily and immediately available, CT with an excretory phase film is considered preferable [77]. US has some desirable features, such as global availability, cost-effectiveness, accessibility in the emergency room, lack of radiation exposure, and accuracy in detecting free fluid in the abdomen as part of the trauma evaluation [79,80]. US may be especially useful for the diagnosis and follow-up of postoperative fluid collections, renal lacerations managed conservatively, and hydronephrosis [81].

IVU (LEVEL 4)

IVU using standard protocols in a radiology department is an appropriate second-line imaging method for haemodynamically stable patients with suspected renal injuries from blunt mechanisms and stab wounds. The IVU must: include nephrotomograms; delineate the renal contour; and fully visualize the excretion of contrast medium from both kidneys into the renal pelvis and ureter. Non-visualization, contour deformity or extravasation of contrast medium implies a major renal injury and should prompt further radiographic evaluation with CT or angiography. The accuracy of IVU and CT has been estimated to be 65–95% in different series, depending on the mechanism of injury [5,6,27,33,70,82]. In patients with renal-proximity stab wounds, IVU as the first diagnostic study was 96% accurate in establishing the presence or absence of injury [45]. IVU is not recommended for staging gunshot wounds [24].

RENAL ARTERIOGRAPHY (LEVEL 5)

Renal arteriography should be considered an adjunct diagnostic imaging technique in the era of helical CT. Indications for angiography

TABLE 4 Indications for renal exploration and levels of supporting evidence

Indication	Description	Level of Evidence
Absolute		
1	Persistent, life-threatening haemorrhage believed to stem from renal injury	(4)
2	Renal pedicle avulsion (grade 5 injury)	(4)
3	Expanding, pulsatile or uncontained retroperitoneal haematoma (thought to indicate renal pedicle avulsion)	(4)
Relative		
1	A large laceration of the renal pelvis, or avulsion of the PUJ	(3)
2	Coexisting bowel or pancreatic injuries	(3)
3	Persistent urinary leakage, postinjury urinoma or perinephric abscess with failed percutaneous or endoscopic management	(3)
4	Abnormal intraoperative one-shot IVU	(3)
5	Devitalized parenchymal segment with associated urine leak	(3)
6	Complete renal artery thrombosis of both kidneys, or of a solitary kidney, or when renal perfusion appears to be preserved	(4)
7	Renal vascular injuries after failed angiographic management	(3)
8	Renovascular hypertension	(4)

include suspected renal arterial thrombosis or segmental arterial injuries (lacerations or pseudoaneurysms) for which interventional radiological treatment (stenting or embolization, respectively) is considered. In renal artery injuries, CT can be diagnostic and hasten operative intervention without angiography [35]. The absence of parenchymal enhancement strongly suggests thrombosis of the main renal artery and does not require confirmation with angiography in most cases. Opacification of the renal vein in a non-enhancing kidney may be an indirect sign of arterial occlusion [83]. Selective embolization of segmental arterial bleeding has become an important component of renal trauma management and will be discussed in subsequent sections of this paper.

HIGH-FIELD MRI (LEVEL 4)

MRI provides excellent detail of the renal anatomy but offers no clear advantage over CT [84,85]. MRI is time-consuming, usually requires complete sequestering of the traumatized patient inside the MR machine, and is not rapidly available in many centres. One further limitation of MRI is a lesser ability to detect urinary extravasation [84]. However, a rare indication for MRI in the renal trauma setting might be severe contrast allergy.

RETROGRADE PYELOGRAPHY (LEVEL 5)

Retrograde pyelography has limited use in the imaging of renal injuries. Contrast

medium extravasation caused by a deep corticomedullary laceration does not routinely require retrograde imaging. Retrograde pyelography is reserved for selected cases in which conventional CT cannot exclude a renal collecting system injury or PUJ avulsion. Failure to opacify the distal ureter on CT should raise the suspicion of an injury to the PUJ, and requires further imaging. Delayed CT 'slices' may resolve such concerns.

FOLLOW-UP IMAGING OF MAJOR RENAL LACERATIONS AND URINARY EXTRAVASATION (LEVEL 4)

Radiographic reassessment of renal trauma is recommended when severe renal injuries have been managed conservatively [86]. The purpose of repeat imaging is to identify patients with worsening urinary extravasation, ongoing significant haemorrhage, and rarer complications such as pseudoaneurysm. Repeat abdominal CT with intravenous contrast medium and delayed scan is recommended 36–48 h after initial scanning for grade 4 and 5 lacerations managed expectantly. Prospective studies are needed to determine whether repeat scanning leads to changes in management that affect the outcome.

Follow-up imaging to document the resolution of urinary extravasation in grade 4 injuries has not been standardized, and some experts recommend little or no subsequent

imaging unless the patient's condition deteriorates (Level 5). Imaging is recommended in those cases when the patient has unexplained fever, flank pain, flank mass, or bleeding. Both CT and US can be useful to identify urinoma or abscess.

MANAGEMENT OF INJURIES

There are few absolute indications for surgical exploration of the kidney in trauma patients, numerous relative indications, and several areas of controversy. The accepted indications and levels of evidence which support these recommendations are shown in Table 4.

PERSISTENT, LIFE-THREATENING BLOOD LOSS (LEVEL 4)

An absolute indication for renal exploration is persistent, life-threatening haemorrhage believed to stem from renal injury [39,71,87–90]. The urologist must be cognisant of the overall condition of the patient and base decisions about urological management accordingly [91]

RENAL PEDICLE AVULSION (LEVEL 4)

The second absolute indication for renal exploration is renal pedicle avulsion (grade 5 injury), which is suspected clinically, by imaging, or by observation of a large, expanding pulsatile haematoma [70,71,87,88,90,92,93]. In patients with renovascular injury haematuria may be absent in 16–20%, so the diagnosis can be difficult [94]. When complete renal artery thrombosis occurs in both kidneys or a solitary kidney, renal exploration and revascularization is indicated [95].

RETROPERITONEAL HAEMATOMA (LEVEL 4)

Treatment of a retroperitoneal haematoma that is not expanding and not pulsatile at the time of emergency laparotomy is controversial. Most blunt injuries may be observed, especially if radiographic studies before and during surgery are normal [74,87]. Some centres also observe penetrating trauma if these radiographic studies show no high-grade injuries. If the imaging is abnormal and the presence of a normal contralateral kidney has been established, the retroperitoneum may be explored [27,96], although this increases the potential for iatrogenic renal loss during the exploration

[97–100]. In general, penetrating renal trauma with a retroperitoneal haematoma in the absence of adequate preoperative staging should be explored and repaired. If exploration is chosen, intraoperative single-shot IVU should be used before exploration. Factors to be considered include patient stability and extent of associated injuries [101] (Level 4). Future studies may delineate which of these patients can be managed nonoperatively. If the decision is made not to explore the kidney despite a retroperitoneal haematoma, then postoperative imaging (i.e. CT) is mandatory [90].

EXTRAVASATION (LEVEL 3)

Urinary extravasation (not resulting from ureteric or renal pelvis injury) alone is not an absolute indication for surgical exploration, as it will resolve spontaneously in 76–87% of cases [25,36,99,102,103]. Intervention (usually with percutaneous or endoscopic methods) is only required when persistent leak, urinoma formation or sepsis develops [90].

Extravasation of urine accompanied by major parenchymal laceration and nonviable parenchyma (>20%) or coexisting bowel or pancreatic injuries, are associated with a higher incidence of major complications (Level 3), and may require a different threshold for operative repair [39,67,71,90,92,99,104,105].

EXTENSIVE RENAL INJURY (LEVEL 3)

A relative indication for renal exploration may be extensive renal injury with gross fragmentation or tissue destruction, even if no other intraperitoneal injury exists [38,39,87,88,90,93,105]. When grade 3 and 4 renal injuries were managed expectantly in some series, delayed renal bleeding occurred in up to 25% of patients [106], but in most cases this can be managed successfully with angiographic embolization [44,45,107].

DEVITALIZED TISSUE (LEVEL 3)

Two studies examining patients with deep renal lacerations and parenchymal fragments indicated that patients with devascularized fragments are associated with a higher complication rate than those with vascularized fragments. Morbidity included bleeding, urinoma formation and abscess [103,108]. These Level 3 studies support early

surgical management in patients with major renal lacerations, devitalized fragments, and associated intraperitoneal injuries [109].

COEXISTING BOWEL OR PANCREATIC INJURIES (LEVEL 4)

Renal exploration may be advisable if there is coexisting bowel or pancreatic injury with extensive renal injury, urinary extravasation and devitalized renal segments [90,93,99,103,108,110]. Renal repair associated with colon, stomach or pancreatic injuries requires the renal area to be well drained; separation of the urinary tract injury from adjacent enteric injury using omentum or other tissue interposition is desirable to isolate any postoperative leak and minimize adverse effects on other local non-urological repairs [91,101]. However, the presence of pancreatic or colonic injury does not necessarily change the indications for an operative or nonoperative approach in patients with significant renal injuries [89,91].

PENETRATING TRAUMA (LEVEL 3)

Immediate exploration of all patients with penetrating renal injuries has been recommended by some [2,88]. However, several studies have shown that in patients with penetrating renal injury, a selective approach can be safely implemented in haemodynamically stable patients [5,44,107,111]. Selection for surgery is indicated in those patients with clinical signs of shock, decreasing haemoglobin level during observation, and radiological signs of extravasation, nonfunction, delayed excretion or hydro-ureteronephrosis from blood clots [111]. Renal exploration is also indicated for all suspected kidney injuries in patients taken to surgery before the radiographic evaluation is completed, patients with major renal injuries (grades 3 and 4) who undergo exploratory laparotomy for other reasons, and all patients with failed angiographic management of renal vascular injuries [45,93].

Gunshot wounds to the kidney may have an increased risk of delayed complications because of extensive tissue damage from the blast effect of the projectile's temporary and permanent cavities, especially in the case of high-velocity missiles or close-range shotguns (Level 4). Thus the threshold for exploring urinary extravasation from gunshot wounds should be lower than that for

exploring blunt trauma or stab wounds [13,90].

PAEDIATRIC RENAL INJURIES (LEVEL 4)

In children with blunt trauma and major renal lacerations (grades 3–5) the indications for surgical exploration include a changing abdominal examination suggestive of a major intra-abdominal injury, or persistent bleeding with haemodynamic instability [37]. However, a significant number of these injuries will heal with no intervention. The safety of watching significant renal injuries in children has been suggested by several studies [19,69], although uncommon but significant complications from untreated renal injuries have been reported [67,68].

RENOVASCULAR TRAUMA (LEVEL 3)

Traumatic injuries to the renal artery and vein are uncommon but usually associated with a significantly injured patient [64]. The difficulty in developing guidelines for managing these patients results not only from the low incidence of the injury but also the lack of prospective cohort studies. If these patients survive they may be left with impaired renal function and risk the delayed development of hypertension or progressive renal failure.

The proportion of renal trauma patients with renovascular injuries is 2.5–4% [1,64,112], most of which are the result of penetrating trauma. In patients with penetrating abdominal and abdominal vascular injuries, renovascular trauma may be present in up to 16% [113,114].

The diagnosis of renal vascular injuries is often delayed, as clinical signs are usually absent; 18–36% of patients will have no haematuria (gross or microscopic) [64,112,114–116]. At laparotomy renal injuries are missed in nearly a quarter of patients in whom a preoperative diagnosis is not made [117–119]. Patients whose injuries are the result of penetrating trauma usually are diagnosed earlier than those whose injuries are the result of blunt trauma [114]. The characteristics of renovascular injuries in selected retrospective series is listed in Table 5. Patients with arterial thrombosis may have little or no retroperitoneal haematoma, have an intact artery, and palpation alone can often miss the diagnosis [64,112,120]. The high rate of associated injuries requiring urgent or emergent intervention increases the

TABLE 5 Characteristics of patients with renovascular injury

Ref	N	Blunt/penetrating (%)	Associated injuries, %	Vascular injury, %*	Nephrectomy rate, %	Mortality rate, %
[94]	96	16/84	95	24 A, 43 V, 33 C	49	21
[123]	94	32/68	95	17 A, 48 V, 35 C	44	37
[112]	41	76/24	100	49 A, 21 V, 15 C, 15 S	39	44
[114]	15	40/60	100	60 A, 27 V, 13 C	60	33
[64]	36	36/64	89	25 A, 31 V, 17 C, 27 S	30	19

A, artery; V, vein; C, combined arterial and venous injury; S, segmental.

TABLE 6 Success rates after revascularization for renal artery laceration and thrombosis

Ref	% Successful outcome
Arterial injury	
[94]	56
[123]	33
[112]	33
[114]	25
[64]	22
Arterial thrombosis	
[122]	29
[125]	64*
[124]	26†

The mean differential renal function was only *21% and †9%.

difficulty in accurately diagnosing renovascular injuries.

Avulsed or lacerated vessels usually mandate renal exploration to control haemorrhage with either ligation of the artery, with or without nephrectomy, or repair of the vessel. In contrast, the management of renal artery occlusion is controversial, with opinions divided between either expectant management or an attempt at immediate revascularization. Options for managing injuries to the segmental branches include observation, transarterial manipulation, exploration, and partial or total nephrectomy, with most experts favouring observation.

SPECIFIC RENOVASCULAR INJURIES (LEVEL 3)

Renal artery occlusion secondary to trauma was first described by Von Recklinghausen in 1861 [121]. Although some reviews report a

high success rate with revascularization [118,122], more recent series suggest that restoring normal renal function is unlikely when the main renal artery is injured [64,94,112,115,123–5].

The success of arterial reconstruction is related to the duration and degree of ischaemia and presence or absence of accessory renal arteries providing collateral flow. In acute, complete, warm renal ischaemia of >2 h irreversible damage ensues [126]. While collateral circulation via the renal capsular, peripelvic and peri-ureteric vessels can maintain some viability for an extended period [126,127], return of function is time-dependent [122,127]. A patent renal vein may also extend viability [116]. The success of renal artery reconstruction can be difficult to interpret because outcomes have not been consistently defined and follow-up tends to be poor in these patients (Table 6).

Reconstructing renal artery injuries should be attempted in patients with single kidneys, bilateral renal injury [127], or when simple arteriorrhaphy is possible. Unilateral injuries should be repaired when the injury is incomplete or recognized early in the presence of a non-ischaemic kidney and a haemodynamically stable patient (Fig. 3A) [64,94,112,114,123]. Incomplete injury, i.e. a defined intimal injury or flap, in which antegrade flow is preserved, represents the least common finding after blunt renovascular trauma, and Level 4 evidence supports expectant management with no operative intervention [128].

Symptomatic renal infarction or hypertension develops in a small subset of patients with arterial injury or thrombosis, in whom delayed nephrectomy may be indicated [122,125,128].

Some authors advocate nephrectomy in these patients if other abdominal exploration is required [115]. However, the low overall proportion of renal trauma patients who develop hypertension does not support such an aggressive approach.

Traumatic branch renal artery injuries are uncommon and rarely require surgical intervention for complications [120]. While some authors advocate renal exploration for segmental arterial lacerations [36,64] angiographic embolization can effectively stop most bleeding from these injuries if necessary (see below) [129].

Renal vein injuries are rare and difficult to identify radiographically. Most are caused by penetrating injuries, the majority of which can be repaired. Blunt trauma may cause avulsion of the renal vein at the level of the inferior vena cava. These injuries may be associated with extensive bleeding and require immediate nephrectomy in 25–50% of cases [123].

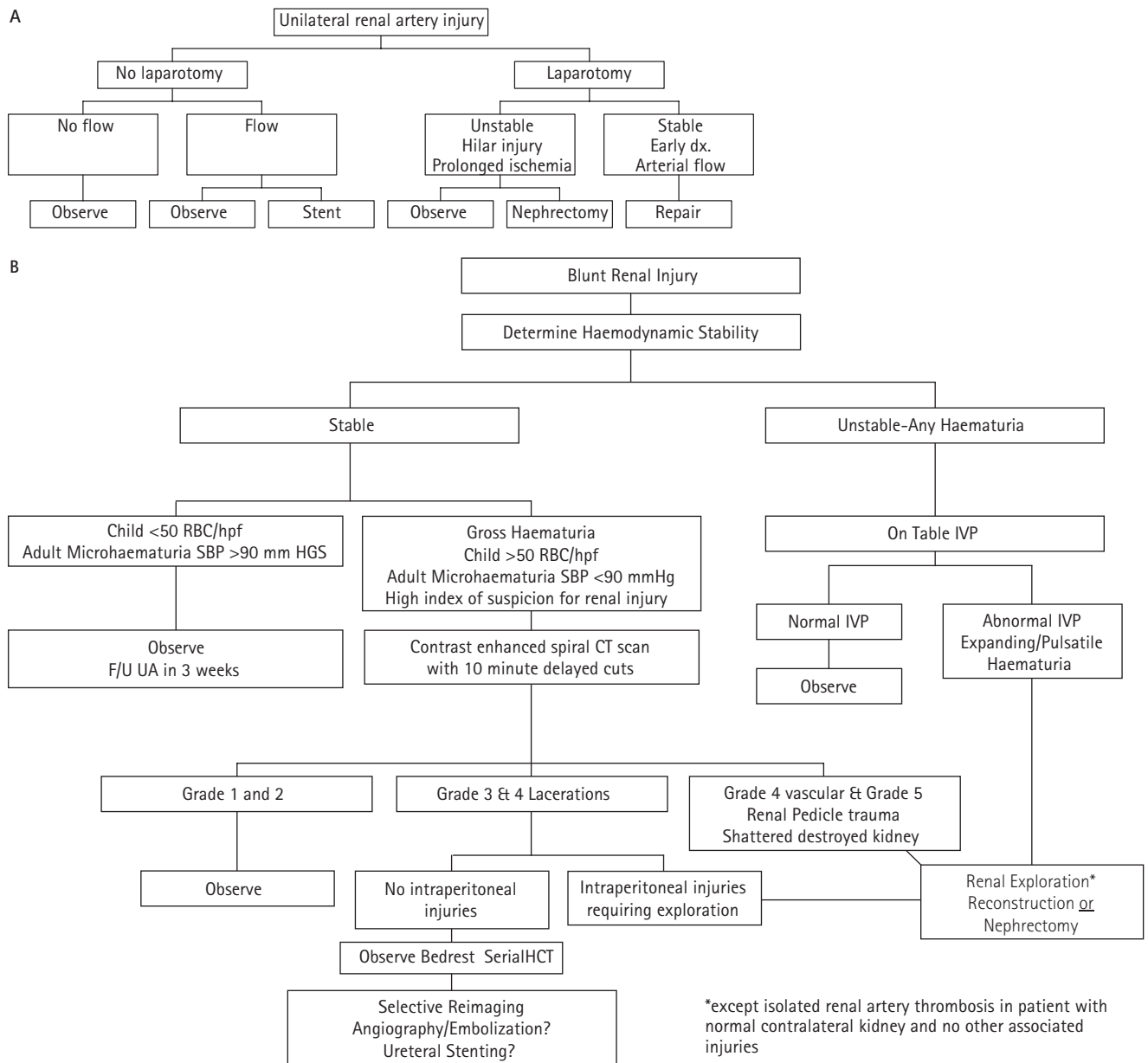
OPERATIVE MANAGEMENT OF RENAL INJURIES

EARLY VASCULAR CONTROL (LEVEL 1 AND 3)

The transperitoneal approach to nephrectomy with early vascular control was first described by Scott and Selzman [130]. McAninch and Carroll [104] reported that such a uniform technique for controlling the renal artery and vein before entering Gerota's fascia reduced nephrectomy rates from 56% to 18%.

Temporary occlusion of the renal vessels is required in a small percentage of patients, and in one study was not associated with an increase in postoperative azotaemia or mortality [25]. Patients who will require temporary vascular occlusion cannot be reliably identified before renal inspection, leading to the recommendation that renal vascular isolation should be used in all patients before exploration. However, not all experts agree with this approach and some do not advocate vascular control (Table 7). One Level 1 study randomized patients managed surgically for penetrating renal injuries to early vascular control or direct exploration of the kidney [131]. Although the authors found no difference in nephrectomy rate or blood loss, methodological flaws in the study make the evidence conflicting, with the weight

FIG. 3. Algorithms for managing: A, renal arterial injury; B, blunt renal injury; and C, penetrating renal injury.



of evidence supporting the recommendation of early vascular isolation.

RENAL RECONSTRUCTION (LEVEL 4)

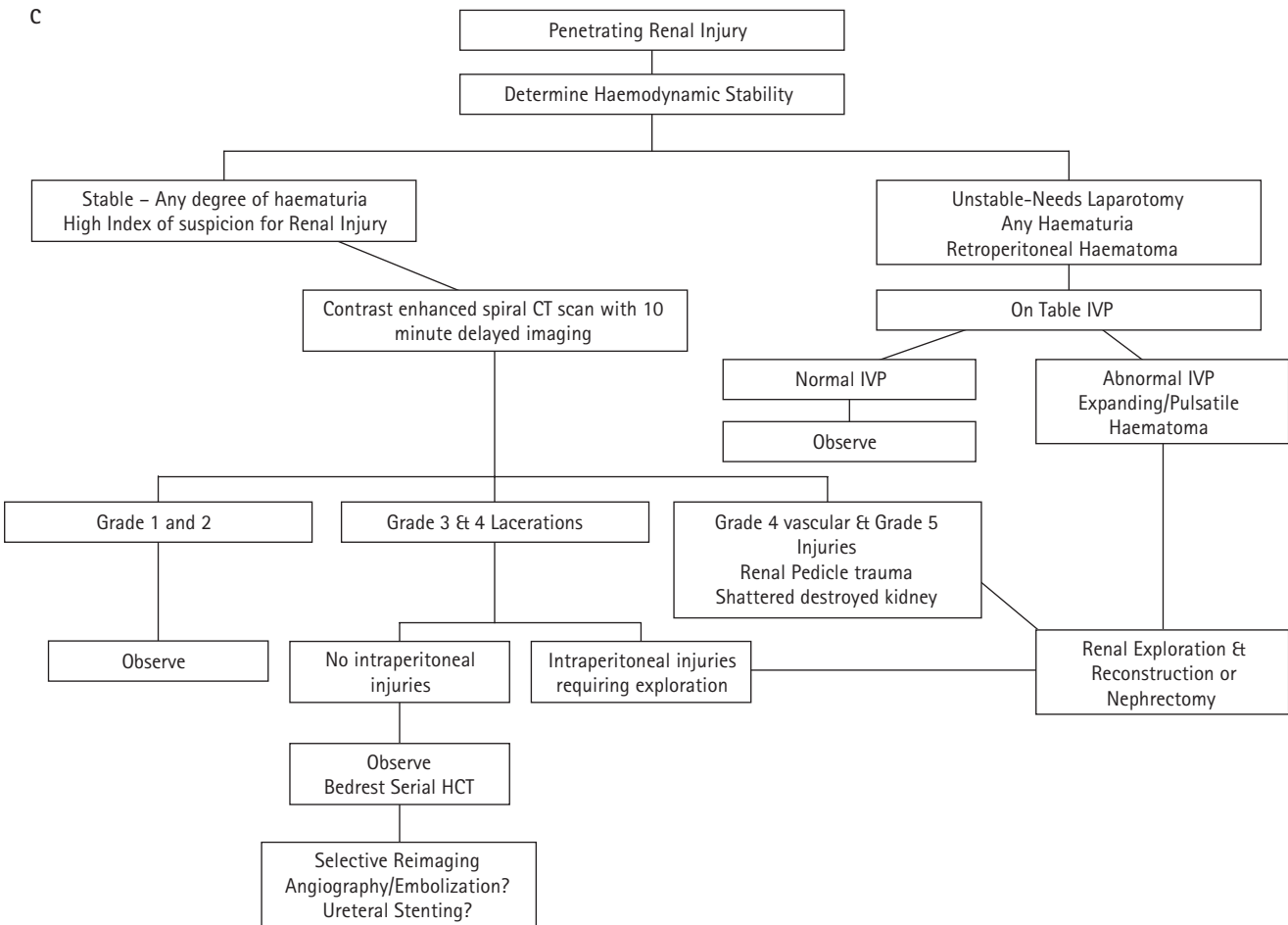
Renal salvage by renorrhaphy or partial nephrectomy requires complete exposure of the injured kidney, debridement of nonviable tissue, suture ligation of bleeding arterial vessels, watertight repair of collecting system injury, and closure of parenchymal defects [25]. Polar injuries can be amputated while lacerations to the middle of the kidney require

renorrhaphy. Haemostasis is obtained by figure-of-eight suture ligation of the bleeding vessels with fine, absorbable suture. The collecting system should be closed in a watertight fashion with a slowly absorbable suture. Defects in the renal parenchyma may be closed primarily in many cases with renal capsule. Perinephric fat, omentum or woven polyglycolic acid mesh may be useful for coverage in cases of larger defects [71,132]. Successful preservation of functioning renal tissue is possible in most renal lacerations requiring exploration, although injury severity, renovascular trauma and associated

TABLE 7 Nephrectomy rates in patients undergoing renal exploration with and with no preliminary vascular isolation

Ref	Vascular control, %	No control, %
[180]	7	53
[104]	18	
[183]	59	37
[88]	30	31
[182]	13	
[131]	31	30

FIG. 3. Continued.



Ref	All patients	Blunt	Penetrating	Gunshot	Stabwound
[46]		36		15	30
[169]*	25				
[88]	31	53	24		
[182]	13	10	14	14	14
[134]	75				
[1]	61	85†	53	62	34

**The likelihood of nephrectomy during a laparotomy for trauma remains low (1.8% overall; 0.3 blunt vs 2.6 penetrating). †Blunt injuries represented 24% of renal explorations, but 84% of injuries overall in this series.*

TABLE 8
Nephrectomy rates (%) for patients undergoing renal exploration. Nephrectomy rates in patients undergoing renal exploration: single institution series and population based studies

injuries may compromise the function of the affected renal unit [35,133].

NEPHRECTOMY (LEVEL 3)

The nephrectomy rate for immediate exploration of major renal lacerations varies considerably (Table 8), depending on the type

and severity of the trauma, but in clinically unstable patients with major renal injury it may reach 100% [38,105,108]. Penetrating mechanism, high-velocity weapons and overall injury severity of the patient are associated with a higher nephrectomy rate (Level 3–4) [1,13]. A high mortality rate for patients after nephrectomy for trauma in one

retrospective cohort series supports the concept that in patients with massive associated injuries, nephrectomy is used for renal injuries that might otherwise be reconstructed [39,98,100,134].

RENOVASCULAR REPAIR (LEVEL 4)

Surgical repair of vascular injuries to the kidney requires specific surgical expertise and a degree of haemodynamic stability. Nephrectomy may be required in 67–86% of patients with main renal artery injuries, in 25–56% of those with main renal vein injuries, and in none with segmental vessel injuries alone [64,135]. Nephrectomy is still the most expeditious method of managing renal vascular injuries, and whereas renal artery repair is rarely possible and seldom successful, renal vein injuries carry a better prognosis [135]. The best outcomes after significant renal artery injury in a recent multicentre review were with immediate (or

delayed when necessary) nephrectomy (Level 3) [35].

In view of the poor results of surgery, arterial revascularization is seldom indicated in patients with a normal contralateral kidney (Level 3) [35,94]. Reconstruction of renal artery injuries should be attempted in patients with single kidneys, bilateral renal injury [127], or when simple arteriorrhaphy is possible [94]. Incomplete arterial lacerations can be sutured primarily. Complete transections often require debridement and segmental excision. Treatment of arterial thrombosis requires excision of the damaged intima in addition to thrombectomy. Reconstruction may be possible with an end-to-end anastomosis, or require interposition grafting with either saphenous vein or prosthetic material.

Auto-grafting with the inferior mesenteric, hypogastric or splenic artery has been reported with limited success in those patients whose associated injuries require removal of these organs. Autotransplantation or removal of the kidney and bench surgery before reimplantation must be rare options.

Injuries to the left renal vein near the vena cava can be managed with ligation, as adequate venous drainage will be provided by the gonadal and adrenal veins. Injuries to the main renal vein on the right must be repaired and this is usually achieved with a lateral venorrhaphy.

ANGIO-EMBOLIZATION (LEVEL 4)

Selective renal artery embolization for managing haemorrhage in stable patients after blunt and penetrating renal trauma has been successful in a growing number of centres. Primary angiographic management of renal vascular injuries has been advocated in stab wounds, with surgical exploration reserved for those in whom it fails [45]. As experience with nonoperative management of major renal injuries accumulates the indications for selective embolization may expand. Functioning renal parenchyma may be lost with embolization, reconstructive surgery and nonoperative approaches. As such, this risk should not deter angiographic approaches in otherwise suitable candidates. The risk of total renal loss may be lower with angio-embolization than exploration of the kidney. Pollack [136] noted that 'embolization to control severe haemorrhage is an attractive therapeutic option, which in the absence of

compelling reasons to do otherwise, should be given serious consideration before embarking on the more formidable surgical option.'

Technical success requires an experienced angiography team that is readily available for emergency intervention. Success rates for embolization of isolated renal artery branch injuries are 70–80% (Level 4) [137,138]. Surgical gelatine, steel coils, or autologous clot can be used to occlude the bleeding vessel. Absorbable materials may lyse and lead to re-bleeding [137]. Arterial branches as small as third- and fourth-order divisions may be successfully embolized, and it can be repeated if necessary, thus obviating surgical intervention and possible nephrectomy. Post-embolization syndrome in these patients occurs in $\approx 10\%$ [111]. Interventional stenting and endovascular techniques may have a role in managing patients with renal arterial thrombosis [139–142]. While the results of case reports (Level 4) are encouraging, a long-term follow-up in many patients is warranted. The same constraints of ischaemia time and associated injuries that limit the success of operative intervention apply for these less invasive alternatives [124]. In the future, patients with severe renovascular injuries (Grade 5) may be approached with endovascular techniques, including stents [92].

FOLLOW-UP IMAGING AFTER INJURY (LEVEL 5)

Expert opinion was used to develop a suggested follow-up imaging protocol after renal injury. For Grade 1 and 2 injuries no follow-up imaging is recommended. Likewise Grade 3 lacerations with no persistent haemodynamic instability or devitalized fragments are unlikely to develop complications and can be observed without imaging.

Grade 4 lacerations with collecting system injuries require follow-up imaging until future studies identify the subset of patients in whom persistent urinary contrast medium extravasation leads to complications. Thus, a repeat CT 36–72 h after injury, consisting of a 10-min delayed image to identify extravasation, is recommended.

The authors of a multicentre study of renovascular trauma advised that all patients who have sustained grade 4/5 renal injuries be evaluated after trauma with documentation of renal function by

quantitative assessment with radionuclide scintigraphy, regardless of the method of treatment [35].

COMPLICATIONS OF RENAL INJURY AND MANAGEMENT

URINOMA AND PERINEPHRIC ABSCESS (LEVEL 3)

Urinary extravasation associated with major renal lacerations will resolve spontaneously in 80–90% of patients [99] and thus many cases can be managed expectantly. In a small subset there may be urinomas and perinephric abscesses. The risk factors for developing these complications include devitalized fragments, coexisting enteric or pancreatic injuries, devitalized colon, infected central venous lines, and large areas of soft-tissue loss requiring debridement. These sources of infection may result in local or systemic seeding of the renal and perinephric tissues [103,108,110].

The urinoma is often asymptomatic but may give rise to vague abdominal or flank discomfort, a palpable mass, an adynamic ileus or low-grade fever [143]. Hydronephrosis, renal displacement or nonvisualization on IVU may suggest the diagnosis. A perirenal low-density collection often with opacification on delayed films is seen with CT. Urinoma development can be quite insidious, with intervals between the date of trauma and the development of symptoms or signs varying from 3 weeks up to 34 years [144].

Historically, urinomas were managed surgically; current endourological techniques now allow the management of persistent urinary leakage and urinoma after injury with percutaneous catheter drainage with or without ureteric stenting [103,143,145]. It also may be considered for an infected urinoma or perinephric abscess as most abdominal abscesses are now managed with percutaneous drainage, with good results. In a review of 100 patients with post-traumatic abscesses, haematomas, empyemas and urinomas, 85% were treated successfully by catheter drainage, thereby avoiding re-operation.

SECONDARY HAEMORRHAGE (LEVEL 4)

Delayed or secondary haemorrhage is a common complication of deep lacerations of

the renal cortex and medulla, especially stab wounds [5,107]. The interval between the injury and the onset of secondary haemorrhage is 2–36 days [5]. It is most often a result of an arteriovenous fistula (AVF) or pseudo-aneurysm [111]. When a large renal artery branch is lacerated together with a large vein in close proximity, the bleeding may initially be tamponaded in the retroperitoneal space. As the haematoma resolves, re-bleeding from the arterial branch may occur, and will be drained into the lacerated vein, thus resulting in an AVF. This can result in very rapid and severe blood loss, with gross haematuria and even clot retention [67]. When grade 3 or 4 renal injuries are managed expectantly, delayed renal bleeding is found in 13–25%, but in most cases this can be managed successfully with angiographic embolization [5,44,45,107,111].

Although there is spontaneous resolution of AVF after renal biopsy in 50–70% of the patients, most AVFs after major renal trauma (especially stab wounds) do not heal spontaneously [111,146]. Hypertension, bruit over the kidney and persistent haematuria are indications for arteriography, but renal perfusion scintigraphy may provide a noninvasive method to detect AVFs [111]. A renal AVF can be treated with nephrectomy, partial nephrectomy, ligation of an arterial bleeder or selective embolization of the involved segmental artery, which can be successful in 82% of cases [111,146].

HYPERTENSION (LEVEL 3)

The pathophysiology of post-traumatic renal hypertension is related to excess renin secretion caused by renal ischaemia. This can be a result of renal arterial thrombosis or injury, or renal parenchymal compression by haematoma or fibrosis, the clinical counterpart of the Page model (reviewed in [121]) [147–149]. Finally, it is also thought that AVF may be a cause of renovascular hypertension after trauma [150]. Small studies have reported specific causes of renovascular hypertension after trauma, e.g. subcapsular haematoma (four of 22 cases), branch artery thrombosis (8/22), renal artery thrombosis (7/22) and diffuse scar formation causing compression (3/22) [150–152].

The incidence of post-traumatic hypertension is also influenced by the severity of renal injury, and the prevalence of pre-existing

essential hypertension, which is affected by the age, sex and race of the population [103]. The pooled mean (range) rate of hypertension after renal injury in published series is 5.2(0.6–33)% (reviewed in [153]). In two series where 214 renal trauma patients were observed for the presence of renovascular hypertension, none was found, although these studies may have been inadequately powered to detect those patients [154,155]. A series of 340 renal injuries showed that 0.3–0.9% developed renovascular hypertension [102].

The time course for developing renovascular hypertension is widely variable and has been reported as 37 days to decades after injury, with a mean of 34 months in one large series from the 1970s [151] (level 4; 11 patients) [152].

Renal artery occlusion may cause hypertension in a significant proportion of those injured. In one series, half of 21 patients with renal artery occlusion developed hypertension, although the hypertension was mild [119]. In a series of renal artery injuries the authors reported hypertension in 32% treated conservatively, in 39% of patients whose revascularization was unsuccessful, and in 33% of those with successful repairs [118]. In a recent case series and literature review, 42% of patients treated expectantly developed hypertension, compared with only 3% patients in whom revascularization was attempted [124]. The evidence to support intervention or nephrectomy to avoid hypertension in patients at high risk of developing hypertension is thus conflicting.

Renal trauma patients at risk of hypertension (Grade 4 and 5 lacerations and vascular injuries) should have periodic blood pressure checks, which should continue in the years after injury (Level 5). Post-traumatic hypertension should be evaluated in selected patients, although guidelines and indications for imaging are not currently available for this selected population.

Nephrectomy is the commonest treatment in the case of renovascular hypertension after trauma [150–152,156–160]. Rare reports of successful repair of arterial stenosis [150,161] or partial nephrectomy for segmental vascular injury have been published [152,162]. The concept of removing the fibrocollagenous shell causing Page

kidney has been suggested, but few patients have been treated successfully [157]. A review in determined that treatment of Page kidney by decortication was successful in less than half the patients [163]. Recently, a laparoscopic operation to decorticate the fibrovascular rind in a probable 'Page kidney' was successful [164]. Finally, successful angiographic embolization (one patient, [165]) and open repair (one patient [166]) of AVF has been reported. Spontaneous regression of renovascular hypertension even after some years has also been reported [156,163].

RENAL INSUFFICIENCY (LEVEL 2)

Studies quantifying the risk of renal insufficiency after renal trauma are lacking. One prospective study reported that renal loss by partial or total nephrectomy for trauma increased the risk of acute renal failure and death [167], but other investigators have not confirmed this relationship [168,169]. A multi-institutional study of 89 patients with grade IV/V renovascular injuries reported post-traumatic renal failure in 6.4%, diminished renal function in 16%, and hypertension in 4.5% [35]. A single-centre series of patients who had grade 3–4 renal injuries reconstructed found that adequate renal preservation, defined as at least a third of the injured kidney, was present in 81% [133]. Angiographic embolization is associated with a 0–10% loss of function of the affected kidney, with most having a 10% decrease [170,171] (Level 4). No data exist on the amount of function lost in the patient with a major renal laceration managed nonoperatively.

CONCLUSIONS

The management of renal trauma has developed over several decades as a result of concerted single-institution efforts to classify kidney lacerations and vascular injuries, and to describe their treatment. Algorithms summarizing the recommendations of the subcommittee are shown in Fig. 3. There are few prospective or multicentre studies. Future research is required in several areas that include: refining the AAST staging classification; better delineating the indications for imaging in children with haematuria after blunt trauma; comparing outcomes of operative, nonoperative and angiographic management of grade 4 and

grade 5 injuries; and determining indications for follow-up imaging of kidney injuries.

REFERENCES

- 1 Wessells H, Suh D, Porter JR *et al.* Renal injury and operative management in the United States: results of a population-based study. *J Trauma* 2003; **54**: 423–30
- 2 Krieger JN, Algood CB, Mason JT *et al.* Urological trauma in the Pacific Northwest: etiology, distribution, management and outcome. *J Urol* 1984; **132**: 70–3
- 3 Hardeman SW, Husmann DA, Chinn HK *et al.* Blunt urinary tract trauma: identifying those patients who require radiological diagnostic studies. *J Urol* 1987; **138**: 99–101
- 4 Ahmed S, Morris LL. Renal parenchymal injuries secondary to blunt abdominal trauma in childhood: a 10-year review. *Br J Urol* 1982; **54**: 470
- 5 Heyns CF, de Klerk DP, de Kock ML. Stab wounds associated with hematuria – a review of 67 cases. *J Urol* 1983; **130**: 228–31
- 6 Wein AJ, Arger PH, Murphy JJ. Controversial aspects of blunt renal trauma. *J Trauma* 1977; **17**: 662–6
- 7 Baverstock R, Simons R, McLoughlin M. Severe blunt renal trauma: a 7-year retrospective review from a provincial trauma centre. *Can J Urol* 2001; **8**: 1372–6
- 8 Santucci RA, McAninch JW, Safir M *et al.* Validation of the American Association for the Surgery of Trauma organ injury severity scale for the kidney. *J Trauma* 2001; **50**: 195–200
- 9 Yarbrow ES, Fowler JE Jr. Renal trauma in rural Virginia. *J Trauma* 1987; **27**: 940–2
- 10 Goff CD, Collin GR. Management of renal trauma at a rural, level I trauma center. *Am Surg* 1998; **64**: 226
- 11 Madiba TE, Haffeeje AA, John J. Renal trauma secondary to stab, blunt and firearm injuries – a 5-year study. *S Afr J Surg* 2002; **40**: 5–10
- 12 Gray N. Renal trauma in a South African hospital: a two year study. *J R Army Med Corps* 1985; **131**: 19–20
- 13 Ersay A, Akgun Y. Experience with renal gunshot injuries in a rural setting. *Urology* 1999; **54**: 972–5
- 14 Quinlan DM, Gearhart JP. Blunt renal trauma in childhood. Features indicating severe injury. *Br J Urol* 1990; **66**: 526–31
- 15 Levy JB, Baskin LS, Ewalt DH *et al.* Nonoperative management of blunt pediatric major renal trauma. *Urology* 1993; **42**: 418–24
- 16 Stein JP, Kaji DM, Eastham J *et al.* Blunt renal trauma in the pediatric population: indications for radiographic evaluation. *Urology* 1994; **44**: 406–10
- 17 Brown SL, Haas C, Dinchman KH *et al.* Radiologic evaluation of pediatric blunt renal trauma in patients with microscopic hematuria. *World J Surg* 2001; **25**: 1557–60
- 18 McAleer IM, Kaplan GW, Scherz HC *et al.* Genitourinary trauma in the pediatric patient. *Urology* 1993; **42**: 563–8
- 19 Morey AF, Bruce JE, McAninch JW. Efficacy of radiographic imaging in pediatric blunt renal trauma. *J Urol* 1996; **156**: 2014–8
- 20 National Trauma Data Bank Report. <http://www.facs.org/Department/Trauma/ntdbannualreport2002.pdf>: Accessed 2002
- 21 <http://hn01.dhs.vic.gov.au/bodw/Home.asp> Accessed 2003
- 22 Radwin HM, Fitch WP, Robison JR. A unified concept of renal trauma. *J Urol* 1976; **116**: 20–2
- 23 Hai MA, Pontes JE, Pierce JM. Surgical management of major renal trauma: a review of 102 cases treated by conservative surgery. *J Urol* 1977; **118**: 7–9
- 24 Nicolaisen GS, McAninch JW, Marshall GA *et al.* Renal trauma: re-evaluation of the indications for radiographic assessment. *J Urol* 1985; **133**: 183–7
- 25 McAninch JW, Carroll PR, Klosterman PW *et al.* Renal reconstruction after injury. *J Urol* 1991; **145**: 932–7
- 26 Carlin BI, Resnick MI. Indications and techniques for urologic evaluation of the trauma patient with suspected urologic injury. *Semin Urol* 1995; **13**: 9–24
- 27 Mendez R. Renal trauma. *J Urol* 1977; **118**: 698–703
- 28 Nation EF, Massey BD. Renal trauma: Experience with 258 cases. *J Urol* 1963; **89**: 775–8
- 29 Salvatierra O Jr, Rigdon WO, Norris DM *et al.* Vietnam experience with 252 urological war injuries. *J Urol* 1969; **101**: 615–20
- 30 Thompson IM, Flaherty SF, Morey AF. Battlefield urologic injuries: the Gulf War experience. *J Am Coll Surg* 1998; **187**: 139–41
- 31 Abu-Zidan FM, Al-Tawheed A, Ali YM. Urologic injuries in the Gulf War. *Int Urol Nephrol* 1999; **31**: 577–83
- 32 Kuvezdic H, Tucak A, Grahovac B. War injuries of the kidney. *Injury* 1996; **27**: 557–9
- 33 Bretan PN Jr, McAninch JW, Federle MP *et al.* Computerized tomographic staging of renal trauma: 85 consecutive cases. *J Urol* 1986; **136**: 561–5
- 34 Mee SL, McAninch JW, Robinson AL *et al.* Radiographic assessment of renal trauma: a 10-year prospective study of patient selection. *J Urol* 1989; **141**: 1095–8
- 35 Knudson MM, Harrison PB, Hoyt DB *et al.* Outcome after major renovascular injuries: a Western trauma association multicenter report. *J Trauma* 2000; **49**: 1116–22
- 36 Cass AS, Luxenberg M, Gleich P *et al.* Long-term results of conservative and surgical management of blunt renal lacerations. *Br J Urol* 1987; **59**: 17–20
- 37 Smith EM, Elder JS, Spirnak JP. Major blunt renal trauma in the pediatric population: is a nonoperative approach indicated? *J Urol* 1993; **149**: 546–8
- 38 Cass AS, Cass BP. Immediate surgical management of severe renal injuries in multiple-injured patients. *Urology* 1983; **21**: 140–5
- 39 McAninch JW, Carroll PR, Armenakas NA *et al.* Renal gunshot wounds: methods of salvage and reconstruction. *J Trauma* 1993; **35**: 279–84
- 40 Rouhana SW. The biomechanics of abdominal trauma. In Nahum AM, Melvin JW eds, *Accidental Injury, Biomechanics and Prevention*. 1st edn. New York: Springer Verlag, 1997: 405
- 41 Schmidlin F, Farshad M, Bidaut L *et al.* Biomechanical analysis and clinical treatment of blunt renal trauma. *Swiss Surg* 1998; **5**: 237–43
- 42 Schmidlin FR, Schmid P, Kurtyka T *et al.* Force transmission and stress distribution in a computer-simulated model of the kidney: an analysis of the injury mechanisms in renal trauma. *J Trauma* 1996; **40**: 791–6
- 43 Farshad M, Barbezat M, Flueller P *et al.* Material characterization of the pig kidney in relation with the biomechanical analysis of renal trauma. *J Biomech* 1999; **32**: 417–25
- 44 Bernath AS, Schutte H, Fernandez RR *et al.* Stab wounds of the kidney:

- conservative management in flank penetration. *J Urol* 1983; **129**: 468–70
- 45 **Eastham JA, Wilson TG, Ahlering TE.** Urological evaluation and management of renal-proximity stab wounds. *J Urol* 1993; **150**: 1771–3
- 46 **Sagalowsky AI, McConnell JD, Peters PC.** Renal trauma requiring surgery: an analysis of 185 cases. *J Trauma* 1983; **23**: 128–31
- 47 **Clasper JC, Hill PF, Watkins PE.** Contamination of ballistic fractures: an *in vitro* model. *Injury* 2002; **33**: 157–60
- 48 **Armenakas NA, Duckett CP, McAninch JW.** Indications for nonoperative management of renal stab wounds. *J Urol* 1999; **161**: 768–71
- 49 **Aubert J, Grange P, Dore B.** [Contusion on horseshoe kidney. Apropos of 2 cases]. *J Urol* 1987; **93**: 455–61
- 50 **Brower P, Paul J, Brosman SA.** Urinary tract abnormalities presenting as a result of blunt abdominal trauma. *J Trauma* 1978; **18**: 719–22
- 51 **Chopra P, St-Vil D, Yazbeck S.** Blunt renal trauma-blessing in disguise? *J Pediatr Surg* 2002; **37**: 779–82
- 52 **Ekeh AP, Patterson L, Anderson G et al.** Isolated traumatic disruption of the ureteropelvic junction in a patient with a solitary kidney. *J Trauma* 2002; **52**: 167–8
- 53 **Esho JO, Ireland GW, Cass AS.** Renal trauma and preexisting lesions of kidney. *Urology* 1973; **1**: 134–5
- 54 **Giyani VL, Gerlock AJ Jr, Grozinger KT et al.** Trauma of occult hydronephrotic kidney. *Urology* 1985; **25**: 8–12
- 55 **Hicks CC, Lewis EL.** Traumatic rupture of horseshoe kidney. *J Trauma* 1977; **17**: 158–60
- 56 **Jonas D, Blume P, Koerner F.** Traumatic kidney rupture in hydronephrosis. *Urol Res* 1975; **3**: 91–4
- 57 **Onen A, Kaya M, Cigdem MK et al.** Blunt renal trauma in children with previously undiagnosed pre-existing renal lesions and guidelines for effective initial management of kidney injury. *BJU Int* 2002; **89**: 936–41
- 58 **Schmidlin FR, Iselin CE, Naimi A et al.** The higher injury risk of abnormal kidneys in blunt renal trauma. *Scand J Urol Nephrol* 1998; **32**: 388–92
- 59 **Moore EE, Shackford SR, Pachter HL et al.** Organ injury scaling: spleen, liver, and kidney. *J Trauma* 1989; **29**: 1664–6
- 60 **Kuo RL, Eachempati SR, Makhuli MJ et al.** Factors affecting management and outcome in blunt renal injury. *World J Surg* 2002; **26**: 416–9
- 61 **MacKenzie EJ, Steinwachs DM, Shankar B.** Classifying trauma severity based on hospital discharge diagnoses. Validation of an ICD-9CM to AIS-85 conversion table. *Med Care* 1989; **27**: 412–22
- 62 **Wessells H.** Evaluation and management of renal trauma in the 21st century. *AUA Updates* 2002; **21**
- 63 **Brandes SB, McAninch JW.** Urban free falls and patterns of renal injury: a 20-year experience with 396 cases. *J Trauma* 1999; **47**: 643–50
- 64 **Carroll PR, McAninch JW, Klosterman P et al.** Renovascular trauma: risk assessment, surgical management, and outcome. *J Trauma* 1990; **30**: 547–54
- 65 **Chandhoke PS, McAninch JW.** Detection and significance of microscopic hematuria in patients with blunt renal trauma. *J Urol* 1988; **140**: 16–8
- 66 **Miller KS, McAninch JW.** Radiographic assessment of renal trauma: our 15-year experience. *J Urol* 1995; **154**: 352–5
- 67 **Teigen CL, Venbrux AC, Quinlan DM et al.** Late massive hematuria as a complication of conservative management of blunt renal trauma in children. *J Urol* 1992; **147**: 1333–6
- 68 **Abdalati H, Bulas DI, Sivit CJ et al.** Blunt renal trauma in children: healing of renal injuries and recommendations for imaging follow-up. *Pediatr Radiol* 1994; **24**: 573–6
- 69 **Russell RS, Gomelsky A, McMahon DR et al.** Management of grade IV renal injury in children. *J Urol* 2001; **166**: 1049–50
- 70 **McAninch JW, Federle MP.** Evaluation of renal injuries with computerized tomography. *J Urol* 1982; **128**: 456–60
- 71 **Santucci RA, McAninch JW.** Diagnosis and management of renal trauma: past, present, and future. *J Am Coll Surg* 2000; **191**: 443–51
- 72 **Kawashima A, Sandler CM, Corriere JN, Jr et al.** Ureteropelvic junction injuries secondary to blunt abdominal trauma. *Radiology* 1997; **205**: 487–90
- 73 **Stevenson J, Battistella FD.** The 'one-shot' intravenous pyelogram: is it indicated in unstable trauma patients before celiotomy? *J Trauma* 1994; **36**: 828–34
- 74 **Morey AF, McAninch JW, Tiller BK et al.** Single shot intraoperative excretory urography for the immediate evaluation of renal trauma. *J Urol* 1999; **161**: 1088–92
- 75 **Thomsen HS, Bush WH.** Adverse effects of contrast media: incidence, prevention and management. *Drug Saf* 1998; **19**: 313–24
- 76 **Jakse G, Furtschegger A, Egender G.** Ultrasound in patients with blunt renal trauma managed by surgery. *J Urol* 1987; **138**: 21–3
- 77 **McGahan JP, Richards JR, Jones CD et al.** Use of ultrasonography in the patient with acute renal trauma. *J Ultrasound Med* 1999; **18**: 207–16
- 78 **Perry MJ, Porte ME, Urwin GH.** Limitations of ultrasound evaluation in acute closed renal trauma. *J R Coll Surg Edinb* 1997; **42**: 420–2
- 79 **Rose SC, Braun SD, Newman GE et al.** Urinary tract injury in patients with blunt chest trauma: the value of post-aortographic abdominal radiographs. *Cardiovasc Intervent Radiol* 1989; **12**: 258–64
- 80 **Dolich MO, McKenney MG, Varela JE et al.** 2,576 ultrasounds for blunt abdominal trauma. *J Trauma* 2001; **50**: 108–12
- 81 **Wessells H, McAninch JW.** Blunt renal trauma: new methods of diagnosis and management. In McGuire EJ ed. *Advances in Urology*. Vol. 9. Chicago: Mosby, 1996; 323–92
- 82 **Erturk E, Sheinfeld J, DiMarco PL et al.** Renal trauma: evaluation by computerized tomography. *J Urol* 1985; **133**: 946–9
- 83 **Cain MP, Matsumoto JM, Husmann DA.** Retrograde filling of the renal vein on computerized tomography for blunt renal trauma: an indicator of renal artery injury. *J Urol* 1995; **153**: 1247–8
- 84 **Leppaniemi A, Lamminen A, Tervahartiala P et al.** Comparison of high-field magnetic resonance imaging with computed tomography in the evaluation of blunt renal trauma. *J Trauma* 1995; **38**: 420–7
- 85 **Marcos HB, Noone TC, Semelka RC.** MRI evaluation of acute renal trauma. *J Magn Reson Imaging* 1998; **8**: 989–92
- 86 **Blankenship JC, Gavant ML, Cox CE et al.** Importance of delayed imaging for

- blunt renal trauma. *World J Surg* 2001; **25**: 1561–4
- 87 **Holcroft JW, Trunkey DD, Minagi H et al.** Renal trauma and retroperitoneal hematomas – indications for exploration. *J Trauma* 1975; **15**: 1045–52
- 88 **Corriere JN Jr, McAndrew JD, Benson GS.** Intraoperative decision-making in renal trauma surgery. *J Trauma* 1991; **31**: 1390–2
- 89 **Wessells H, McAninch JW.** Effect of colon injury on the management of simultaneous renal trauma. *J Urol* 1996; **155**: 1852–6
- 90 **Meng MV, Brandes SB, McAninch JW.** Renal trauma: indications and techniques for surgical exploration. *World J Urol* 1999; **17**: 71–7
- 91 **Rosen MA, McAninch JW.** Management of combined renal and pancreatic trauma. *J Urol* 1994; **152**: 22–5
- 92 **Knudson MM, Maull KI.** Nonoperative management of solid organ injuries. Past, present and future. *Surg Clin North Am* 1999; **79**: 1357–71
- 93 **Safir MH, McAninch JW.** Diagnosis and management of trauma to the kidney. *Curr Opin Urol* 1999; **9**: 227–31
- 94 **Brown MF, Graham JM, Mattox KL et al.** Renovascular trauma. *Am J Surg* 1980; **140**: 802–5
- 95 **Carroll PR.** Renovascular trauma. Evaluation and management. *Prob Urol* 1994; **8**: 1
- 96 **Cass AS, Luxenberg M, Gleich P et al.** Management of perirenal hematoma found during laparotomy in patient with multiple injuries. *Urology* 1985; **26**: 546–9
- 97 **Hammer C, Santucci RA.** Effect of an institutional policy of nonoperative treatment of grade I–IV renal injuries. *J Urol* 2003; **169**: 1751–3
- 98 **Altman AL, Haas C, Dinchman KH et al.** Selective nonoperative management of blunt grade 5 renal injury. *J Urol* 2000; **164**: 27–31
- 99 **Matthews LA, Smith EM, Spirnak JP.** Nonoperative treatment of major blunt renal lacerations with urinary extravasation. *J Urol* 1997; **157**: 2056–8
- 100 **Perego KL, Little DC, Kirkpatrick AK.** Conservative nonoperative management of Grade 5 blunt renal trauma. *J Urol* 2001; **165**: 14
- 101 **Coburn M.** Damage control for urologic injuries. *Surg Clin North Am* 1997; **77**: 821–34
- 102 **Peterson NE.** Fate of functionless post-traumatic renal segment. *Urology* 1986; **27**: 237–42
- 103 **Husmann DA, Gilling PJ, Perry MO et al.** Major renal lacerations with a devitalized fragment following blunt abdominal trauma: a comparison between nonoperative (expectant) versus surgical management. *J Urol* 1993; **150**: 1774–7
- 104 **McAninch JW, Carroll PR.** Renal trauma: kidney preservation through improved vascular control – a refined approach. *J Trauma* 1982; **22**: 285
- 105 **Kristjansson A, Pedersen J.** Management of blunt renal trauma. *Br J Urol* 1993; **72**: 692–6
- 106 **Wessells H, McAninch JW, Meyer A et al.** Criteria for nonoperative treatment of significant penetrating renal lacerations. *J Urol* 1997; **157**: 24–7
- 107 **Heyns CF, De Klerk DP, De Kock ML.** Nonoperative management of renal stab wounds. *J Urol* 1985; **134**: 239–42
- 108 **Husmann DA, Morris JS.** Attempted nonoperative management of blunt renal lacerations extending through the corticomedullary junction: the short-term and long-term sequelae. *J Urol* 1990; **143**: 682–4
- 109 **Moudouni SM, Patard JJ, Manunta A et al.** A conservative approach to major blunt renal lacerations with urinary extravasation and devitalized renal segments. *BJU Int* 2001; **87**: 290–4
- 110 **Moudouni SM, Hadj Slimen M, Manunta A et al.** Management of major blunt renal lacerations: is a nonoperative approach indicated? *Eur Urol* 2001; **40**: 409–14
- 111 **Heyns CF, Van Vollenhoven P.** Selective surgical management of renal stab wounds. *Br J Urol* 1992; **69**: 351–7
- 112 **Cass AS, Bubrick M, Luxenberg M et al.** Renal pedicle injury in patients with multiple injuries. *J Trauma* 1985; **25**: 892–6
- 113 **Scott R Jr, Carlton CE Jr, Goldman M.** Penetrating injuries of the kidney. an analysis of 181 patients. *Trans Am Assoc Genitourin Surg* 1968; **60**: 169–74
- 114 **Meacham PW, Brock JW, Kirchner FK et al.** Renal vascular injuries. *Am Surg* 1986; **52**: 30–6
- 115 **Haas CA, Dinchman KH, Nasrallah PF et al.** Traumatic renal artery occlusion: a 15-year review. *J Trauma* 1998; **45**: 557–61
- 116 **Clark DE, Georgitis JW, Ray FS.** Renal arterial injuries caused by blunt trauma. *Surgery* 1981; **90**: 87–96
- 117 **Dinchman KH, Spirnak JP.** Traumatic renal artery thrombosis: evaluation and treatment. *Semin Urol* 1995; **13**: 90–3
- 118 **Lock JS, Carraway RP, Hudson HC et al.** Proper management of renal artery injury from blunt trauma. *South Med J* 1985; **78**: 406–10
- 119 **Stables DP, Fouche RF, de Villiers van Niekerk JP et al.** Traumatic renal artery occlusion: 21 cases. *J Urol* 1976; **115**: 229–33
- 120 **Bertini JE Jr, Flechner SM, Miller P et al.** The natural history of traumatic branch renal artery injury. *J Urol* 1986; **135**: 228
- 121 **Von Rechlinghausen F.** Haemorrhagische Niereninfarkete. *Arch Path Anat Physiol* 1861; **20**: 205
- 122 **Maggio AJ Jr, Brosman S.** Renal artery trauma. *Urology* 1978; **11**: 125–30
- 123 **Turner WW Jr, Snyder WH 3rd, Fry WJ.** Mortality and renal salvage after renovascular trauma. A review of 94 patients treated in a 20 year period. *Am J Surg* 1983; **146**: 848–51
- 124 **Haas CA, Spirnak JP.** Traumatic renal artery occlusion: a review of the literature. *Tech Urol* 1998; **4**: 1–11
- 125 **Glenski WJ, Husmann DA.** Traumatic renal artery thrombosis: Management and long term followup. *J Urol* 1995; **153**: 316A
- 126 **Culp DA.** Renal arterial block. *Surg Gynecol Obstet* 1969; **129**: 114–5
- 127 **Lohse JR, Shore RM, Belzer FO.** Acute renal artery occlusion: the role of collateral circulation. *Arch Surg* 1982; **117**: 801–4
- 128 **Kaufman JL, Dinerstein CR, Shah DM et al.** Renal artery intimal flaps after blunt trauma: indications for nonoperative therapy. *J Vasc Surg* 1988; **8**: 33–7
- 129 **Fisher RG, Ben-Menachem Y, Whigham C.** Stab wounds of the renal artery branches: angiographic diagnosis and treatment by embolization. *Am J Roentgenol* 1989; **152**: 1231–5
- 130 **Scott RF Jr, Selzman HM.** Complications of nephrectomy: review of 450 patients and a description of a modification of the transperitoneal approach. *J Urol* 1966; **95**: 307–12

- 131 Gonzalez RP, Falimirski M, Holevar MR *et al.* Surgical management of renal trauma: is vascular control necessary? *J Trauma* 1999; **47**: 1039–44
- 132 Delany HM, Ivatury RR, Blau SA *et al.* Use of biodegradable (PGA) fabric for repair of solid organ injury: a combined institution experience. *Injury* 1993; **24**: 585–9
- 133 Wessells H, Deirmenjian J, McAninch JW. Preservation of renal function after reconstruction for trauma: quantitative assessment with radionuclide scintigraphy. *J Urol* 1997; **157**: 1583–6
- 134 Di Giacomo JC, Rotondo MF, Kauder DR *et al.* The role of nephrectomy in the acutely injured. *Arch Surg* 2001; **136**: 1045–9
- 135 Ivatury RR, Zubowski R, Stahl WM. Penetrating renovascular trauma. *J Trauma* 1989; **29**: 1620–3
- 136 Pollack HM. Renal trauma: imaging and intervention. *Problems Urol* 1994; **8**: 199–219
- 137 Uflacker R, Paolini RM, Lima S. Management of traumatic hematuria by selective renal artery embolization. *J Urol* 1984; **132**: 662–7
- 138 Kantor A, Sclafani SJ, Scalea T *et al.* The role of interventional radiology in the management of genitourinary trauma. *Urol Clin North Am* 1989; **16**: 255–65
- 139 Whigham CJ Jr, Bodenhamer JR, Miller JK. Use of the Palmaz stent in primary treatment of renal artery intimal injury secondary to blunt trauma. *J Vasc Interv Radiol* 1995; **6**: 175–8
- 140 Goodman DN, Saibil EA, Kodama RT. Traumatic intimal tear of the renal artery treated by insertion of a Palmaz stent. *Cardiovasc Intervent Radiol* 1998; **21**: 69–72
- 141 Villas PA, Cohen G, Putnam SG, 3rd *et al.* Wallstent placement in a renal artery after blunt abdominal trauma. *J Trauma* 1999; **46**: 1137–9
- 142 Paul JL, Otal P, Perreault P *et al.* Treatment of posttraumatic dissection of the renal artery with endoprosthesis in a 15-year-old girl. *J Trauma* 1999; **47**: 169–72
- 143 Morano JU, Burkhalter JL. Percutaneous catheter drainage of post-traumatic urinoma. *J Urol* 1985; **134**: 319–21
- 144 Thompson IM, Latourette H, Montie JE *et al.* Results of non-operative management of blunt renal trauma. *Trans Am Assoc Genitourin Surg* 1976; **68**: 128–31
- 145 Wilkinson AG, Haddock G, Carachi R. Separation of renal fragments by a urinoma after renal trauma: percutaneous drainage accelerates healing. *Pediatr Radiol* 1999; **29**: 503–5
- 146 Marshall FF, White RI Jr, Kaufman SL *et al.* Treatment of traumatic renal arteriovenous fistulas by detachable silicone balloon embolization. *J Urol* 1979; **122**: 237–9
- 147 von Knorring J, Fyhrquist F, Ahonen J *et al.* Renin/angiotensin system in hypertension after traumatic renal-artery thrombosis. *Lancet* 1976; **1**: 934–6
- 148 Scott PL, Yune HY, Weinberger MH. Page kidney: an unusual cause of hypertension. *Radiology* 1976; **119**: 547–8
- 149 Braasch WF, Strom GW. Renal trauma and its relation to hypertension. *J Urol* 1943; **50**: 543
- 150 Montgomery RC, Richardson JD, Harty JI. Posttraumatic renovascular hypertension after occult renal injury. *J Trauma* 1998; **45**: 106–10
- 151 Grant RP Jr, Gifford RW Jr, Pudvan WR *et al.* Renal trauma and hypertension. *Am J Cardiol* 1971; **27**: 173–6
- 152 Meyrier A, Rainfray M, Lacombe M. Delayed hypertension after blunt renal trauma. *Am J Nephrol* 1988; **8**: 108–11
- 153 Watts RA, Hoffbrand BI. Hypertension following renal trauma. *J Hum Hypertens* 1987; **1**: 65–71
- 154 Slade N. Management of closed renal injuries. *Br J Urol* 1971; **43**: 639–45
- 155 Maling TJ, Little PJ, Maling TM *et al.* Renal trauma and persistent hypertension. *Nephron* 1976; **16**: 173–80
- 156 von Knorring J, Fyhrquist F, Ahonen J. Varying course of hypertension following renal trauma. *J Urol* 1981; **126**: 798–801
- 157 Carini M, Selli C, Trippitelli A *et al.* Surgical treatment of renovascular hypertension secondary to renal trauma. *J Urol* 1981; **126**: 101–4
- 158 Abel BJ, Kennedy JH. Severe hypertension following traumatic renal infarction. *Br J Urol* 1978; **50**: 54
- 159 Sterns RH, Rabinowitz R, Segal AJ *et al.* 'Page kidney'. Hypertension caused by chronic subcapsular hematoma. *Arch Intern Med* 1985; **145**: 169–71
- 160 Klein FA, Elkins LE. Renal hypertension following conservative management of blunt renal trauma. *J Tenn Med Assoc* 1987; **80**: 550–3
- 161 Depner TA, Sullivan MJ, Ryan KG *et al.* Posttraumatic renal artery stenosis. Cure of hypertension by late revascularization. *Arch Surg* 1975; **110**: 1150–1
- 162 Peterson NE, Norton LW. Injuries associated with renal trauma. *J Urol* 1973; **109**: 766–8
- 163 Sufrin G. The Page kidney: a correctable form of arterial hypertension. *J Urol* 1975; **113**: 450–4
- 164 Castle EP, Herrell SD. Laparoscopic management of page kidney. *J Urol* 2002; **168**: 673–4
- 165 Angus LD, Tachmes L, Kahn S *et al.* Surgical management of pediatric renal trauma: an urban experience. *Am Surg* 1993; **59**: 388–94
- 166 Morin RP, Dunn EJ, Wright CB. Renal arteriovenous fistulas: a review of etiology, diagnosis, and management. *Surgery* 1986; **99**: 114–8
- 167 McGonigal MD, Lucas CE, Ledgerwood AM. The effects of treatment of renal trauma on renal function. *J Trauma* 1987; **27**: 471–6
- 168 Cass AS, Cerra FB, Luxenberg M *et al.* Renal failure and mortality after nephrectomy for severe trauma in multiply-injured patient: no inordinate risk. *Urology* 1987; **30**: 213–5
- 169 Narrod JA, Moore EE, Posner M *et al.* Nephrectomy following trauma – impact on patient outcome. *J Trauma* 1985; **25**: 842–4
- 170 Khan AB, Reid AW. Management of renal stab wounds by arteriographic embolisation. *Scand J Urol Nephrol* 1994; **28**: 109–10
- 171 Eastham JA, Wilson TG, Ahlering TE. Radiographic evaluation of adult patients with blunt renal trauma. *J Urol* 1992; **148**: 266–7
- 172 Herschorn S, Radomski SB, Shoskes DA *et al.* Evaluation and treatment of blunt renal trauma. *J Urol* 1991; **146**: 274–7
- 173 Cass AS, Luxenberg M, Gleich P *et al.* Clinical indications for radiographic evaluation of blunt renal trauma. *J Urol* 1986; **136**: 370–1
- 174 McAndrew JD, Corriere JN. Jr. Radiographic evaluation of renal trauma: evaluation of 1103 consecutive patients. *Br J Urol* 1994; **73**: 352–4

- 175 **Lieu TA, Fleisher GR, Mahboubi S *et al.*** Hematuria and clinical findings as indications for intravenous pyelography in pediatric blunt renal trauma. *Pediatrics* 1988; **82**: 216–22
- 176 **Fleisher G.** Prospective evaluation of selective criteria for imaging among children with suspected blunt renal trauma. *Pediatr Emerg Care* 1989; **5**: 8–11
- 177 **Bass DH, Semple PL, Cywes S.** Investigation and management of blunt renal injuries in children. a review of 11 years' experience. *J Pediatr Surg* 1991; **26**: 196–200
- 178 **Middlebrook PF, Schillinger JF.** Hematuria and intravenous pyelography in pediatric blunt renal trauma. *Can J Surg* 1993; **36**: 59–62
- 179 **Hashmi A, Klassen T.** Correlation between urinalysis and intravenous pyelography in pediatric abdominal trauma. *J Emerg Med* 1995; **13**: 255–8
- 180 **Carlton CE Jr, Scott R Jr, Goldman M.** The management of penetrating injuries of the kidney. *J Trauma* 1968; **8**: 1071–83
- 181 **Atala A, Miller FB, Richardson JD *et al.*** Preliminary vascular control for renal trauma. *Surg Gynecol Obstet* 1991; **172**: 386–90
- 182 **Nash PA, Bruce JE, McAninch JW.** Nephrectomy for traumatic renal injuries. *J Urol* 1995; **153**: 609–11

Correspondence: H. Wessells, Department of Urology, Harborview Medical Center, 325 Ninth Avenue, Seattle WA 98104, USA.
e-mail: wessells@u.washington.edu

Abbreviations: SIU, Société Internationale d'Urologie; AAST, American Association for the Surgery of Trauma; SBP, systolic blood pressure; US, ultrasonography; AVF, arteriovenous fistula.